

Case Report

TRIPLE RIGHT RENAL VEINS AND BILATERAL MULTIPLE RENAL ARTERIES—A CASE REPORT

Saransh Girdhar*, Vinay Sharma*, Om Prakash Gupta**, Arjun Singh**, C.S.Ramesh Babu*

* Department of Anatomy Muzaffarnagar Medical College, Muzaffarnagar

** Dr. O.P.Gupta Imaging Center, Sumer Bhawan, Bachcha Park, Meerut.

ABSTRACT

Most frequently encountered renal vascular anomalies are the presence of supernumerary renal vessels. Thorough knowledge of the renal vascular anatomy and its variants is essential for pre-operative planning. Renal arterial anomalies are more common on the left side and venous anomalies on the right side. An incidental finding of supernumerary renal vessels in a male patient undergoing multidetector computed tomography angiography is presented here. Three right renal veins, independently emerging from the hilum and draining into inferior vena cava, were observed. The reported incidence of this variant varies from 1.0 % to 4.5 %. The single left renal vein was having the normal preaortic course. Left kidney received two renal arteries and the right kidney three renal arteries. The lower two right renal arteries had an anomalous precaval course to reach the right kidney. Presence of bilateral multiple renal arteries associated with supernumerary right renal veins is rarely reported.

KEY WORDS : Supernumerary renal vessels, Triple right renal veins, Precaval right renal artery, Renal vascular variation.

INTRODUCTION : Renal vascular anomalies are frequently encountered and understanding their anatomy is most crucial for anatomists, radiologists and surgeons. Normally each kidney is supplied by a single renal artery and drained by a single renal vein. The left renal vein (LRV) averages 6 - 10 cm in length and crosses in front of aorta just below the origin of superior mesenteric artery to join medial aspect of inferior vena cava (IVC) The shorter right renal vein (RRV), about 2 – 4 cm long, joins the lateral aspect of IVC directly.[1] Normally, the right renal vein has no tributary draining into it, in contrast, the left renal vein receives left gonadal vein, left adrenal vein, left inferior phrenic vein and left lumbar vein . Renal arteries arise as lateral branches of aorta opposite to the level of upper border of L2 vertebra. The longer

right renal artery (RRA) passes posterior to IVC (retrocaval course) to reach renal hilum. At the renal hilum the renal vein is generally placed anterior to renal artery.

The most frequently encountered renal vascular variation is the presence of supernumerary renal vessels.[2] Numerical variations of renal arteries are more common on the left side and venous anomalies are common on the right side.[3] Bilateral multiple renal arteries are reported to occur in 5 % to 15 % cases [4, 5] and multiple right renal veins can occur in up to 30% individuals.[1] Accurate pre-operative depiction of renal vascular variants is essential for successful accomplishment of renal and other retroperitoneal surgeries. We report here incidental finding of triple right renal veins and bilateral multiple renal arteries in a male patient evaluated by

ADDRESS FOR CORRESPONDENCE:

C.S. Ramesh Babu,
Associate Professor of Anatomy,
Muzaffarnagar Medical College,
N.H.58, Opp. Begrajpur Industrial Area,
Muzaffarnagar- 251203.

multidetector computed tomography (MDCT) angiography.

CASE REPORT : Renal vascular anomalies were observed incidentally in a 28 year old male patient who underwent MDCT angiography for suspected hepatobiliary pathology. The MDCT angiography was performed by a 64 channel scanner (GE Optima-60) and the patient received 90 ml of non-ionic contrast (Omnipaque, 300 mg I/ml) intravenously at the rate of 4 ml/s by a power injector. Written informed consent was obtained from the patient before contrast injection. Sections of 0.625 mm thick were obtained and analysed in a separate work station (AW Volume share 4.5) to generate volume rendered (VR) and maximum intensity projection (MIP) images. Hepatobiliary system did not show any pathology but renal vascular variants were incidentally noted.

Right kidney was drained by three renal veins arising independently from the hilum and draining into IVC. The lower RRV passes downwards to join IVC at the level of L3 vertebra. The upper two RRVs join IVC opposite to the level of LRV. LRV has a normal preaortic course. (Figure-1) The right kidney is supplied by three arteries and the lower two right renal arteries (RRAs) have a precaval course crossing in front of IVC, to reach the right kidney. (Figure-1, 2) The main RRA has a normal retrocaval course . Of the

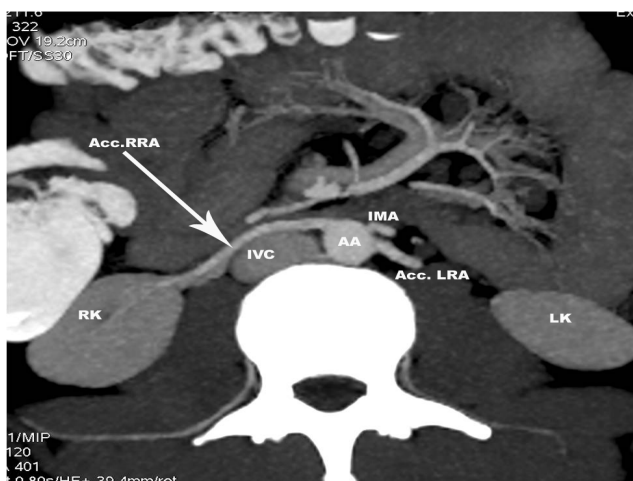


Figure-1: Axial section at the level of third lumbar vertebra showing precaval course (large arrow) of lower right renal artery (Acc RRA). AA- Abdominal aorta; Acc.LRA- Accessory left renal artery; IMA- Inferior mesenteric artery; IVC- Inferior vena cava; LK- Left kidney; RK- Right kidney.

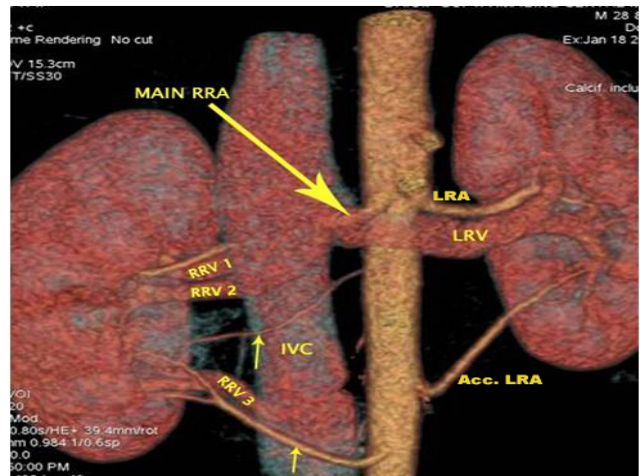


Figure-2: Volume rendered image showing both renal vein and renal artery variations observed in a 28 year old male patient. The left renal vein (LRV) has a normal preaortic course. Three right renal veins (RRV1, RRV2, RRV3) drain the right kidney and separately open into inferior vena cava (IVC). The left kidney receives two renal arteries (LRA, Acc.LRA) and the right kidney three renal arteries. The main right renal artery (large arrow) has a normal retrocaval course to reach right renal hilum. The lower two right renal arteries (small arrows) have anomalous precaval course crossing in front of IVC.

two accessory RRAs, one was arising just below the level of LRV and the other arise below the level of inferior mesenteric artery. Left kidney is supplied by two arteries (LRAs). The main LRA passes above the LRV to enter hilum. The accessory LRA arises opposite to the level of inferior mesenteric artery and passes upwards to reach the lower pole.

DISCUSSION : Numerical variations of the renal vessels are frequently encountered. Multiple renal vein anomalies are more common on the right side.[6, 7] Supernumerary renal vein is defined as an additional renal vein arising from the renal hilum separately and draining into IVC. Three RRVs were found in 3.2 % of 156 pairs of autopsied kidneys [6] and in 1 out of 102 live renal donors[7]. Bapista-Silva et al (1997) has observed three or more RRVs in 3 subjects out of 31 cases of living donor nephrectomy of right kidney[8]. Kawamoto et al (2005) in their MDCT angiographic study on 100 living laparoscopic renal donors reported an incidence of multiple RVs in 22 % cases on the right side (21 with double RRVs and only 1 case with triple RRVs) and

none on the left side[9]. Presence of triple right renal veins has been reported in cadaveric studies also[10, 11, 12]. Tao et al (2013) reported a 4.0 % incidence of triple right renal veins[13].

Bergman et al (1988) reported that double renal arteries occur in about 10 % of cases and triple renal arteries occur in about 1-2 % of cases (based on collective studies on 10967 kidneys)[14]. In another study on 440 kidneys, double renal arteries were noted in 23.2 % cases and triple renal arteries in 4.5 % cases[3]. Natsis et al (2014) in their study on 103 cadavers reported the presence of triple renal arteries in 3 cases[15]. Bilateral renal artery variations were observed in 4.5 % of 378 subjects[13]. In the present case two accessory right renal arteries had precaval course crossing anterior to IVC. It is suggested that such precaval right renal arteries may compress the ureter causing hydronephrosis and can be mistaken for right gonadal artery which normally cross anterior to IVC.

During development renal arteries arise as lateral splanchnic branches from the dorsal aorta, common iliac and internal iliac arteries. During the process of ascent of the kidney, as the more caudally placed renal arteries regress, new cranially placed renal arteries arise to supply the developing kidney. When the kidneys reach their normal position, the definitive renal arteries from the aorta persist and any additional arteries supplying the kidneys degenerate. Persistence of these lateral splanchnic arteries results in the presence of multiple renal arteries. Three pairs of longitudinal venous channels in communication with each other develop successively in the form of posterior cardinal. Subcardinal and supracardinal veins and give rise to IVC. Renal veins are formed by anastomoses of the subcardinal and supracardinal veins. Initially the renal veins form as ventral and dorsal venous channels ; regression of the dorsal and persistence of ventral channels result in the development of renal veins.

CONCLUSION : Accurate depiction of renal vascular anomalies is very important for proper pre-operative evaluation and selection of patients undergoing laparoscopic living donor nephrectomy and other operative and interventional procedures in the renal area. Venous anomalies constitute a potential

surgical nightmare, if not documented pre-operatively. MDCT angiography is a sensitive, non-invasive radiological procedure depicting renal and vascular anomalies, aiding accurate pre-operative evaluation.

REFERENCES

1. Urban BA, Ratner LE, Fishman EK. Three-dimensional volume-rendered CT angiography of the renal arteries and veins: Normal anatomy, variants and clinical application. *Radiographics*. 2001; 21: 373-386.
2. Aragao JA, Gomes HL, Costa HVD, Marcelo IS, Nunes PS. Double right renal vein: Clinical and surgical implications and review of the literature. *Int J Basic Appl Sci*. 2015; 4(2): 178-182.
3. Satyapal KS, Haffejee AA, Singh B, Ramsaroop I, Robbs JV, Kaliden JM. Additional renal arteries: Incidence and morphometry. *Surg Radiol Anat*. 2001; 23(1): 33-38.
4. Ozkan U, Oguzkurt L, Tercan F, Kizilkilic O, Koc Z, Koca N. Renal artery origins and variations: Angiographic evaluation of 855 consecutive patients. *Daign Interv Radiol*. 2006; 12: 183-186.
5. Pollak R, Prusak RF, Mozes MF. Anatomic abnormalities of cadaver kidneys procured for purposes of transplantation. *Am Surg*. 1986; 52: 233-235.
6. Ballesteros LE, Saldarriaga V, Ramirez LM. Morphologic evaluation of the renal veins: a study with autopsy material from Colombian subjects. *Rom J Morphol Embryol*. 2014; 55(1): 77-81.
7. Patil UD, Raghavan A, Nadaraj, Murthy K, Shankar R, Bastani B, Ballal SH. Helical CT angiography in evaluation of live kidney donors. *Nephrol Dialysis Transplant*. 2001; 16: 1900-1904.
8. Bapista-Silva JCC, Verissimo MJ, Castro MJ, Camara ALG, Pestana JOM. Anatomical study of the renal veins observed during 342 living donor nephrectomies. *Sao Paulo Med J/RPM*. 1997; 115(3): 1456-1459.
9. Kawamoto S, Lawler LP, Fishman EK. Evaluation of the renal venous system on late arterial and

- venous phase images with MDCT angiography in potential living laparoscopic renal donors. *Am J Roentgenol. (AJR)* 2005; 184: 539-545.
10. Gupta A, Gupta R, Singal R. Congenital variations of renal veins: Embryological background and clinical implications. *J Clin Diagn Res.* 2011; 5(6): 1140-1143.
 11. Fernandes RMP, Conte FHP, Favorito LA, Abidu-Figueiredo M, Babinski MA. Triple right renal vein: An uncommon variation. *Int J Morphol.* 2005; 23(3): 231-233.
 12. Mishra GP, Bhatnagar S, Singh B. Unilateral triple renal veins and bilateral double renal arteries – An unique case report. *Int J Anat Res.* 2014; 2(1): 239-241.
 13. Tao X-F, Zhu J-Q, Wu Y-W, Tang G-Y, Shi Y-Z, Zhang L, Lin Y, Wang Z-Q. Dual-energy computed tomography angiography for evaluating the renal vascular variants. *Chin Med J.* 2013; 126(4): 650-654.
 14. Bergman RA, Thompson SA, Afifi AK, Saadeh FA. *Compendium of human anatomic variations.* Baltimore. Urban & Schwazenberg. 1988.
 15. Natsis K, Paraskevas G, Panagouli E, Tsaraklis A, Lolis E, Piagkou M, Venieratos D. A morphometric study of multiple renal arteries in Greek population and a systematic review. *Rom J Morphol Embryol.* 2014; 55 (3 Suppl): 1111-1122.