

Original Article

HISTOGENESIS OF FETAL KIDNEY IN FETUSES OF DIFFERENT GESTATIONAL AGE GROUPS

Khayati Sant Ram*, Anshu Sharma**, Mahesh Sharma**, Naresh Goel***, Daisy Sahni*

* Dept. of Anatomy, Post Graduate institute of medical education and research, Chandigarh, INDIA.

** Dept. of Anatomy, Government Medical College & Hospital, Chandigarh, INDIA

*** Dept. of Anatomy, Hind institute of medical sciences, Barabanki, Lucknow, UP, INDIA

ABSTRACT

The study was done to assess the development of human fetal kidney. The present study was carried out in the department of Anatomy, Government Medical College & Hospital, Chandigarh. The material for the study consisted of 30 spontaneously aborted human fetal specimens from 12th to 30th weeks of gestational ages. The kidneys were taken from fetal specimens for histological study. Slides were prepared. Hematoxylin and eosin was done. It was observed nephrogenic zone decreased as gestation advanced, PCT and DCT were more prominent after 18th week of gestation. Cortico medullary differentiation was seen in later gestational period. It was thought that an understanding of histology of fetal kidneys would elucidate pathogenesis of abnormal kidney.

Keywords : glomeruli, proximal convoluted tubule, distal convoluted tubule, kidney, cortex, medulla, nephrogenic zone,

INTRODUCTION : It is important to know the normal developmental anatomy and histogenesis of urinary system for better understanding of various congenital renal conditions. Kidney plays a vital role in development of fetuses. Accurate assessment of gestational age of fetuses is essential for both clinical and medicolegal point of view. Prenatal development is a very crucial period for human development

Embryologically, Kidneys develop from intermediate mesoderm of human embryos in cranio-caudal direction. These are pronephric kidney, mesonephric kidney and metanephric kidney. Metanephros appears in lumbosacral segments, develop in 5th week. It develops from Ureteric bud which forms collecting part and metanephrogenic blastema forms secretory part. Ureteric bud its distal

end dilates and invades the caudal part of nephrogenic cord dorsal to mesonephric ridge. It repeatedly divides. It is capped with a metanephric blastema on further sub-division some parts of the blastema separate from the main mass and form clusters of cells on each side of the tubule forms pear shaped hollow renal vesicles. First vesicle is formed at the end of 7th week. Cells at the proximal pole of the vesicles organize to form C-shaped or comma shaped body followed by cellular reorganization of tubular cells at distal end to form an 'S' shaped body or S-body. In the cleft of the S-body at the distal pole, formation of extra cellular matrix and penetration by capillaries targets at formation of future mesangial region. The proximal limb of the S-body organizes to form distal convoluted tubule while the intermediate

Address for Corresponds

Name : Khayati Sant Ram

Institution: Dept.: Dept of Anatomy, Research block B, PN Chuttani block, post graduate institute of medical education and research, Chandigarh, India

City: Chandigarh Country: India

E-mail: khayati_santram@yahoo.com

limb enlarges to form loop of Henle and the proximal convoluted tubule resulting in entire development of a nephron[1,2,3,4,8,10].

Many such nephrons are present in the fetal kidney due to multiple branching of the ampullary bud and induction of various mesenchymatous condensates to form nephron arcades. The permanent kidneys become functional in intrauterine life and urine produced by them is added to amniotic fluid from 10th week of gestation.

MATERIALS AND METHOD : The present study was carried out in the department of Anatomy, Government Medical College & Hospital, Chandigarh. The material for the study consisted of 30 aborted human fetal specimens from 12th to 28th weeks of gestational ages. The specimens were provided by the department of Obstetrics & Gynaecology Government Medical College & Hospital, Chandigarh for routine fetal autopsy. All fetuses were result of the intra uterine death or spontaneous abortion. Consent for autopsy and brief antenatal, medical, past history from the mother was taken from the parents to perform the study. Histological slides were made and stained with Haematoxylin and eosin.

The fetuses were divided into three groups according to the gestational age :

GROUPS	GESTATIONAL AGE	NUMBER OF FETUSES
A	11-18 weeks	7
B	>18-25 weeks	11
C	>25 weeks	12

OBSERVATION

Group A (11-18 weeks)

Capsule was identified , it was made up of thin collagen fibres and fibroblasts. Beneath the capsule a zone was present known as nephrogenic zone the cells in this zone were oval, with eosinophilic cytoplasm and centrally placed nucleus. Some cells were scattered and some were in the groups (fig 1). Beneath this zone growing ureteric bud in form of ampulla was seen, the cells were cuboidal to columnar with centrally placed nucleus (fig 2). Hollow

structures lined by single layer of cells were seen these were nephrogenic vesicles. Glomeruli were observed, they were in there developing stage, and between the developing glomeruli in the connective tissue developing tubules were seen. Tubules were lined by cuboidal cells with pale eosinophilic cytoplasm. Bowman's space was crescentic enclosing few capillaries. The visceral and parietal layers of Bowman's capsule were lined by simple columnar and low cuboidal epithelium respectively. Proximal and distal convoluted tubules were not differentiated. Medulla consisted of loose connective tissue with mesenchymal cells. Cortex and medulla cannot be differentiated at this age.

Group B (>18-25 weeks)

Capsule was present. Nephrogenic zone was reduced compared to previous gestational age groups. Glomeruli were bilobed were more in number.

Proximal and distal convoluted tubule was identified. PCT had irregular lumen lined by cuboidal cells with brush border with euchromatic nuclei. DCT had large lumen lined by cuboidal cells without brush border with euchromatic nuclei. The proliferating capillaries invaginated the concave visceral wall of Bowman's capsule showing beginning of lobulations .Medulla collecting tubules were seen, lined by columnar epithelium. Thick loop of henle was lined by cuboidal epithelium and thin segment was lined by squamous epithelium(fig 3).

Group C (>25 weeks)

In the cortex DCT and PCT were increased, connective tissue was less; many capillaries are seen adjacent to the glomeruli (fig 4,5). In medulla more number of collecting tubules, thin and thick loop of henle were seen. Thickness of cortex and medulla increased with increase in gestational age(fig 6).

DISCUSSION

Few authors found nephrogenic zone was seen just beneath the capsule as a broad and continuous zone in earlier weeks of gestation but as fetal age increased the size of nephrogenic zone decreased and it was absent at 38 weeks of gestation indicating that after 38 weeks of gestation new nephrons were not formed[5,7].

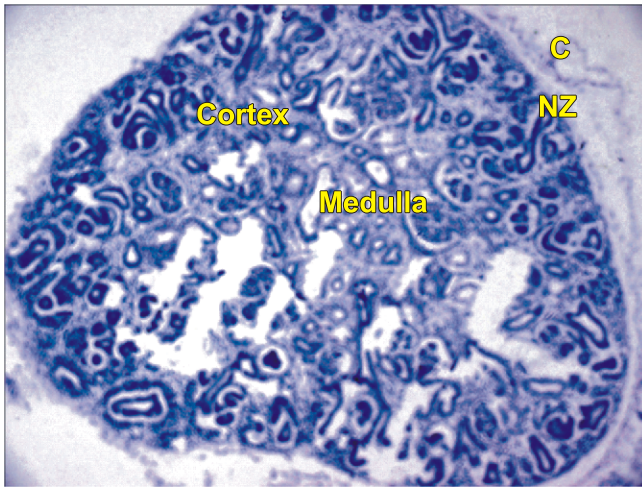


Fig 1 :- Nephrogenic zone(NZ)beneath the capsule with undifferentiated cortex and medulla at 16th week of gestation. H&E 40X

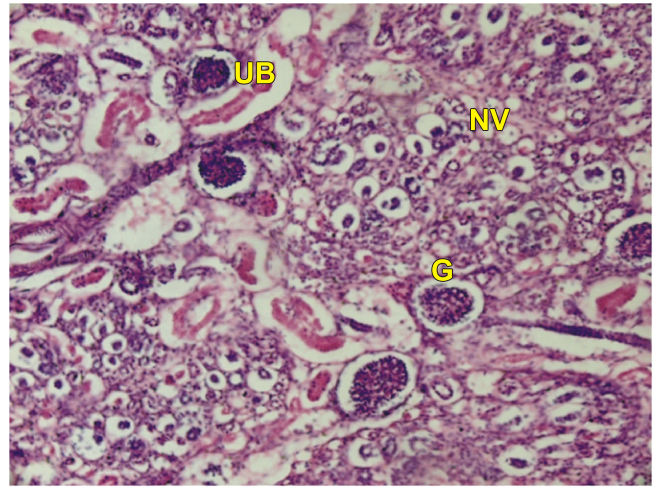


Fig 2 : Nephrogenic vesicle (NV) and Ureteric bud (UB) in the cortex with mature and immature glomeruli (G) formation at 18th week of gestation. H&E 60X

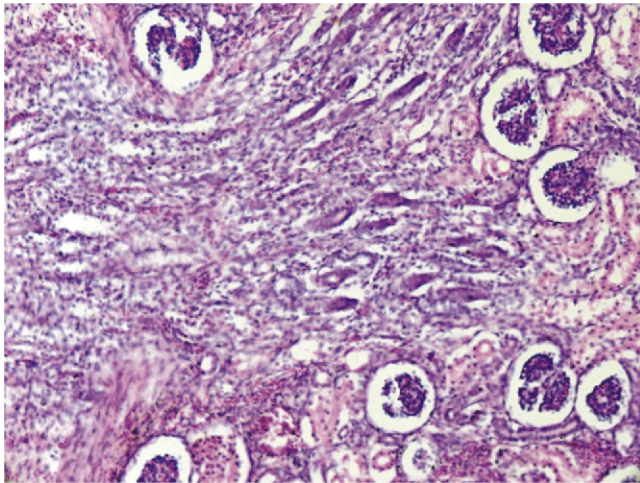


Fig 3 : Cortex with mature and immature glomeruli (G) and tubule formation at 20 weeks of gestation. H&E 60X

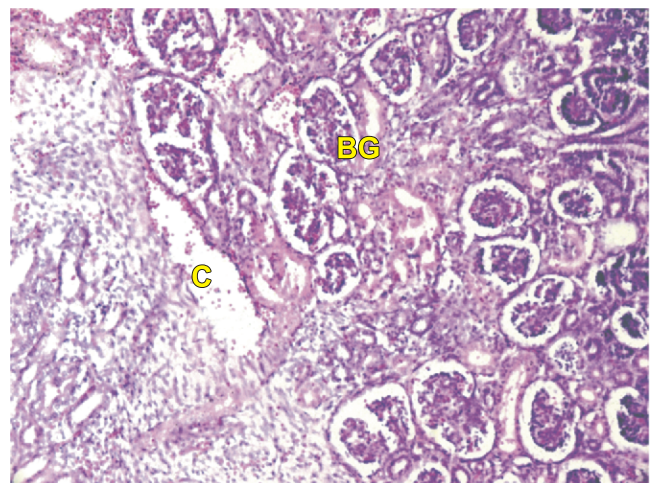


Fig 4 : Increased capillaries (C) are seen adjacent to bilobed glomeruli at 26 weeks gestation . H&E 60X

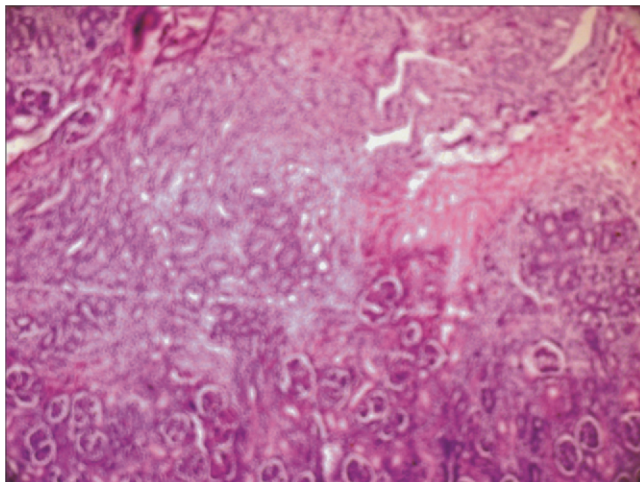


Fig 5 : Cortex and medulla at 25 weeks of gestation . H&E 40X

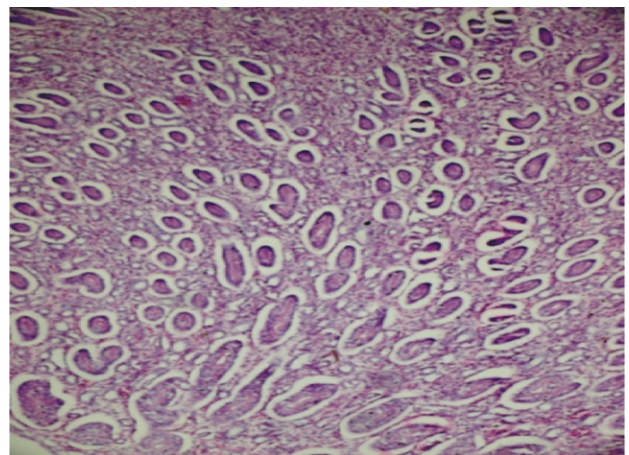


Fig 6:- Increased number of tubules in medulla at 26 weeks gestation. H&E 60X

In a study it was seen persistence of nephrogenic zone upto 3-6 months after birth suggesting that new nephron formation continues postnatally[1]. In our study nephrogenic zone was seen upto 28 weeks; nephrogenic cells had faint eosinophilic cytoplasm and dark staining oval nuclei indicating mitosis.

Helena Maria et al 6 had found immature renal corpuscles till 35 weeks whereas Arne Ljungqvist 4 found rudimentary renal corpuscles even at full term. According to Moore 3 the number of glomeruli increased from 10th to 32nd week gestation. In our study the number of mature renal corpuscles went on increasing with increasing gestational age.

The number of proximal and distal convoluted tubules went on increasing as gestational age advanced. In our study more number of mature renal corpuscles and tubules were seen in deeper part than in superficial part of cortex. These findings suggest that cortex of kidney differentiates from deeper to superficial part. Maria H et al 6 also had similar findings.

In our study immature renal corpuscles were seen in superficial part and more mature renal corpuscles were seen in deeper part of cortex. Immature renal corpuscles were seen in more number in early part of gestational period and they were present till 30 weeks.

Ljungqvist A 4 found out that as gestational age increased the number of well differentiated tubules in medulla increased. But Ljungqvist A 4 had not mentioned regarding the time when collecting tubules and Henle's loop appeared in medulla. Tank et al 9 observed PCT and DCT at 17th week, Sudha P et al 7 found them at 18th week our study also had similar finding.

CONCLUSION

An understanding of histology of fetal kidneys would elucidate pathogenesis of abnormal kidney so the present study was carried out.

REFERENCES

1. Campos E.S. Pathological changes in kidney in congenital syphilis John.Hopk.Hosp.Bull 1923; 34: 253-262.
2. Hamilton W.J. Boyd and Mossman. Histogenesis of metanephrons. Human Embryology. 4th ed. The University of Michigan Heffer Publication 1972;383-391.
3. Keith L. Moore and T.V.N. Persaud. Development of urinary system. The developing Human. 7th ed. The University of Michigan Saunders publisher 2003; 288-292
4. Ljungqvist A. Fetal and post natal development of intrarenal arterial pattern in man: A microangiographic and histologic study. Acta Paediatrica 1963; 52: 443-464.
5. Morag S, Donald M, John L. The late intrauterine and postnatal development of human renal glomeruli. Journal of Anatomy 1959; 93:331-340
6. Maria H, Lizardo D et al. Diagnosis of the human age based on the development of normal kidney. Journal Brasileiro de patologia e medicina Laboratorial 2002; 38(2):1-10
7. Sudha P ,Prabhakar P, Abhay M. Histogenesis of human fetal kidney. NJIRM. 2012; 3(3):122-127.
8. Sadler T.W. Urogenital system Langman's medical embryology 9th Ed. Lippincott Williams and Wilkins Baltimore 2006; 229-238
9. Tank KC, Saiyad SS, Pandya AM et al .A study of histogenesis of human fetal kidney. Int J Biol Med Res.2012; 3(1):1315-1321
10. William J. Larsen. Development of urogenital system. Human Embryology 3rd Ed. Churchill Livingstone Publishers Philladelphia 2001; 273.