

Original Article

HISTOLOGICAL PROFILE OF LIVER OF ALBINO RATS ON ORAL ADMINISTRATION OF SODIUM BENZOATE

Amit Agarwal,* Archana Sharma*, G.L.Nigam,* Antima Gupta,* V.D. Pandey*, Anuj Malik,* Arvind Yadav *

* Department of Anatomy LLRM Medical college, Meerut

ABSTRACT

The present study evaluates the histological effects of oral sodium benzoate on liver of albino rats. The study comprises of 4 groups of albino rats. Each group consists of 10 albino rats. Of these, first group was given 400mg/kg body weight sodium benzoate orally in distilled water, second group was given 800mg/kg body weight sodium benzoate in distilled water, and the third group was given 1200mg/kg body weight sodium benzoate in distilled water and the fourth group served as a control which received distilled water only. All rats were sacrificed at the end of 30 days. The changes which occurred in rats as compared to control were swelling (vacuolization), disorganization of hepatocytes, dilated central vein, hemorrhage, and syncytium formation. These alterations became more pronounced in liver of rats administered higher doses of sodium benzoate.

INTRODUCTION

Humans are exposed to complex mixtures of chemical compounds in their food. One of these substances are antioxidants which are used as food preservatives. Preservatives are added into the products for preventing and delaying losses due to microbiologic, enzymatic or chemical changes and for prolonging shelf life [1]. The food additives mean any substance that is normally used as typical ingredient of the food [2]. Such substances are introduced into food to improve appearance, taste and aroma (e.g. colouring matters, flavouring agent and emulsifiers) and keeping good food qualities (antioxidant, preservation) such as: sodium benzoate which is a widely used food preservative in many foods [3,4]. It is used in soft drinks, fruit products, pickles and sauces [5]. It is classified as 'class 2' preservative and is also present naturally in many food stuffs and in plant extracts. In physical form it is solid and its chemical formula is $\text{NaC}_7\text{H}_5\text{O}_2\text{Na}$.

The present study has been conducted to elucidate histological changes in the liver of albino rats on oral administration of sodium benzoate.

MATERIAL AND METHODS

The present study was conducted in the department of Anatomy, LLRM Medical College after obtaining approval from the Institutional Ethical Committee. Total 40 albino rats weighing 150 to 200 gm were used for the study. They were maintained in the animal house under controlled conditions and were allowed to acclimatize for 3 weeks before the experiment.

Forty rats were grouped as follows:

Treated group: first group was given 400mg/kg body weight sodium benzoate orally in distilled water, second group was given 800mg/kg body weight sodium benzoate in distilled water, and the third group was given 1200mg/kg body weight sodium benzoate in distilled water. All rats were sacrificed at the end of 30 days. All these treated groups consisted of ten rats each.

Control group: ten animals were administered 2ml distilled water orally. All animals were fed with a nozzle fitted into a measuring syringe.

The rats were sacrificed and liver dissected out and immediately preserved in 10% formalin solution. This solution was discarded after 24 hours and

Address for Correspondence :

Dr. Amit Agarwal

JR-III, Department of Anatomy LLRM Medical College,
Meerut

another fresh solution taken and tissue preserved for secondary fixation.

After suitable fixation the tissue underwent standard steps of dehydration, clearing and wax impregnation. After this sections of 4-5 μm thick were cut and stained with haematoxylin and eosin stain.

OBSERVATIONS

In the present study remarkable increase in histopathological changes in liver of albino rats during treatment periods were observed as compared to control group. Fig 1 shows liver of control rats which were administered distilled water only. Distortion of hepatic architecture was observed in all the treated groups. In the group of 400 mg dose of sodium benzoate, liver of rats showed loss of most of the architecture of liver with dilated central vein (Fig. 2)

In the 800 mg dose group liver showed cytoplasmic vacuolization of hepatocytes (Fig. 3).

In the 1200 mg dose group liver showed dilated central vein and formation of syncytium with interstitial hemorrhage (Fig.4).

Marked enlarged vacuolated cytoplasm (cellular swelling), loss of most of the architecture of liver, dilated central vein, are a constant finding in all the sodium benzoate treated dose groups. Interstitial hemorrhage and syncytium formation is seen only in 1200 mg dose group while venous bleeding is seen in 800 mg and 1200 mg dose group.

The above findings are summarized below.

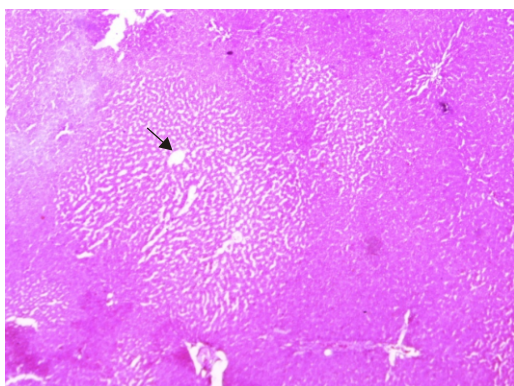


Fig. 1 (10 \times magnification): A photomicrograph of a liver section of control rats administered with sodium benzoate for 30 days showing polyhedral hepatocytes and their radiation from central vein (arrow).

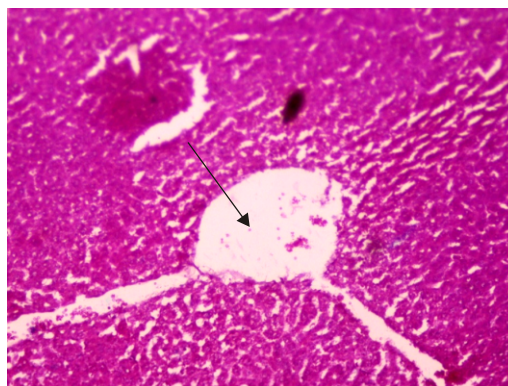


Fig.2 (10 \times magnification): A photomicrograph of a liver section of rats administered with sodium benzoate 400 mg for 30 days showing dilated central vein (arrow) and loss of architecture of liver.

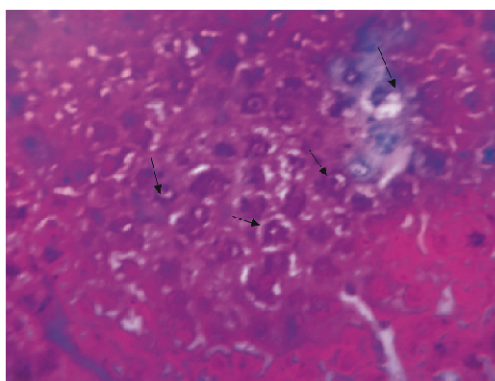


Fig.3 (40 \times magnification): A photomicrograph of a liver section of rats administered with sodium benzoate 800mg for 30 days showing swelling (vacuolization) of hepatocytes (arrows).

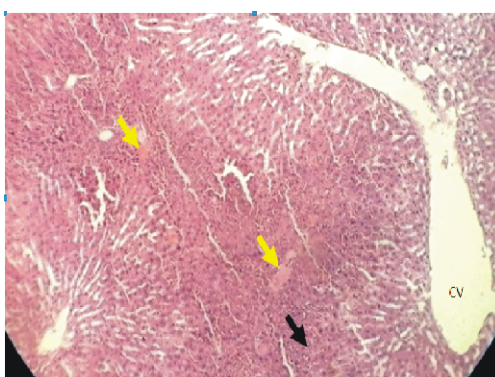


Fig.4 (10 \times magnification): A photomicrograph of a liver section of rats administered with sodium benzoate 1200mg for 30 days showing dilated central vein (CV) and syncytium formation (black arrow) and interstitial hemorrhage (yellow arrows).

Table: Observation

Observation	Control (10 rats)	400 mg (10 rats)	800 mg (10 rats)	1200 mg (10 rats)
Distortion of hepatic architecture	–	8	10	10
Dilated central vein	–	7	7	9
Vacuolated cytoplasm of hepatocytes	–	6	7	7
Interstitial hemorrhage	-	-	-	6
Venous bleeding	–	–	6	6
Syncytium	–	–	-	7

DISCUSSION

It is evident from the present study that the administration of sodium benzoate resulted in distinctive alteration of architecture of liver and on increasing the dose the histopathological changes in liver were increased on serial increment of dose of sodium benzoate from 400 mg to 1200 mg.

The drug administered resulted in swelling (vacuolization), disorganization of hepatocytes, dilated central vein, hemorrhage, and syncytium formation.

Similar swelling of hepatocytes were also obtained by Fujitani(1993) [6], Aktac et al (2003) [7], Sinha and D’Souza (2010) [8]. Khidir et al (2012) [9] and Bakar and Aktac (2014) [10].

Distortion of hepatic architecture was also obtained by all the above workers. Distortion of hepatic architecture was also reported by Aktac et al (2003) [7] with another preservative citric acid in addition to sodium benzoate. Similar findings were also seen in our study.

In the present study dilated central vein was seen which was also reported in a study by Khidir et al (2012) [9] with sodium benzoate.

In the present study interstitial hemorrhage is seen in 1200 mg dose group Khidir et al (2012) [9] found hemorrhage in areas of degenerated hepatocytes after 90 days of sodium benzoate administration at a dose of 1gm/kg body weight.

The venous bleeding was seen with 800 mg and 1200 mg dose of sodium benzoate in our study. This has not been reported by above workers and only small venule bleeding is reported by Xiaoguang et al (2013) [11] with another preservative, citric acid.

Syncytium formation is seen in our study in 1200 mg dose only.

D’souza (2012) [12]. Khidir et al (2012) [9], and Bakar, Aktac (2014) [10] obtained same results with sodium benzoate.

In the present study, cellular swelling could be due to cell organelle degeneration especially mitochondria with subsequent decrease in sodium and potassium pumps followed by accumulation of water. Swelling of some hepatocytes was also reported by Fujitani (1993) and Sinha and D’ Souza (2012) on F344 rat and mice after the administration of sodium benzoate.

Dilated central vein and hemorrhage could be due to noxious effect of the drug causing rupture of the vessel wall and may be dose dependent and may depend also on the duration of administration of the drug.

Syncytium formation, an important feature especially after administration of sodium benzoate, at a dose of 1200 mg for 30 days was noticed in the present study. Elwi et al (1973) [13] explained that the earliest changes in the dead cells were swelling of their cytoplasm due to imbibitions of fluid inside the cell and apparent coagulation of their cytoplasm. Subsequently the cells lose their cell membranes and become indistinct from each other. EL-Banhawy and Ganzuri (1978) [14] attributed this symptom to the noxious effects of several drugs on the lysosomal membranes. These membranes, which are very sensitive to any pathological effect, are ruptured and then release their powerful enzymes, which cause degeneration and dissolution of various cellular components.

Khidir et al (2012) [9] found hemorrhage in areas of degenerated hepatocytes after 90 days of sodium

benzoate administration at a dose of 1gm/kg body weight. He used rats in the range of 200 to 300 gms. That means a 200 gms. rat was fed 200 mg. of sodium benzoate for 90 days but in our study hemorrhage is widespread and is found even after 30 days of sodium benzoate administration probably due to higher doses used up to a maximum of 1200 mg.

Hence the present study showed that sodium benzoate caused considerable damage to liver of rats. Sodium benzoate induced swelling (vacuolization), disorganization of hepatocytes, dilated central vein, hemorrhage, and syncytium formation.

Acknowledgement

Dr. Manish Saini, Veterinary Officer LLRM Medical College

REFERENCES

1. Schacer, R., "Sialic acids : fascinating sugars in higher animals and man", *Zoology (Jena)*, 2004., 107: 49-64.
2. Food and Agriculture Organisation (FAO)/World Health Organisation (WHO) - General standard for the prepackaged foods , Rev-1995. In *Codex Alimentarius, Volume 1A. Joint FAO/WHO Food Standards Programme, Rome, 1995.*, 1A: 245.
3. Marmion, D.M. in *Handbook of U.S. Colorants for Food, Drugs and Cosmetics*. 2nd ed., John Wiley and Sons., 1984.
4. Stoewsand, G., How toxic is sodium benzoate *Food science and technology, Cornell University Int. J Devl Neuroscience*, 2000., 18: 367-381.
5. Srour, R., Benzoic acid and derivatives. In: Srour R. ed. *Aromatic intermediates and derivatives* 1998., 212(2):1-17.
6. Fuzitani, Y. Short-term effect of sodium benzoate in F344 rats and B6C3F1 mice. *Toxicology letters*. 1993., 69: 171-179.
7. Aktac, T., Kaboglu A., Ertan F., Ekinci F. Huseyinova, G. The effects of citric acid (antioxidant) and benzoic acid (antimicrobial agent) on the mouse liver: Biochemical and histopathological study, *Biologia Bratislava. (section Cellular and Molecular Biology)* 2003., 58(3): 343-347.
8. Sinha, R., D'Souza, D. Liver Cell Damage Caused Due to Sodium Benzoate Toxicity in Mice . *International Journal of Biotechnology and Biochemistry*. 2010., 6(4): 549-554 .
9. Khidr BM, Makhlof MMM and Ahmed SMM. Histological and ultrastructural study on the effect of Sodium benzoate on the liver of adult male albino rats. *Assiut Univ. J. of Zoology* 2012; 41(1), 11-39
10. Bakar E., Aktac T. Effects of Sodium Benzoate and Citric Acid on Serum, Liver and Kidney Tissue Total Sialic Acid Levels: An Ultrastructural Study. *Journal of Applied Biological Sciences.*, 2014, 8(2): 09-15.
11. Cheng, Qiongxia, Yumei Liu and Wen Deng: Study on injury effect of food additive citric acid on liver tissue in mice; *Cytotechnology*, 2014 ; 66 (2): 275-282.
12. Sinha R, D'Souza D .Intraperitoneally induced liver cell damage in swiss albino mice . *Asian J Med Cli Sci* 2012; 1(2): 89-91
13. Elwi, M. A; Saleh, A. S, and Kamel, A. I. : *Textbook of pathology*. Chapter 4, 6th edn., 1973: pp. 31-46
14. El-Banhawy, M. A. and Ganzuri, M. A. Pathological effects of insecticides on acid phosphatase containing particles in mammalian liver cells. *Proc. Egypt Soc. Environ. Sci.* 1978., 1: 55-70.