

Original Article

# PYRAMIDAL LOBE AND LEVATOR GLANDULAE THYROIDAE IN HUMAN FETAL THYROID GLAND.

Navodita Chaudhary\*, Richa Niranjana\*, A.K.Singh\*, D.N. Sinha\*, M.K.Pant\*,

\* Department of Anatomy. Govt Medical College, Haldwani (U.K.)

## ABSTRACT

The thyroid gland is very important endocrine gland which starts differentiating at very early stage because it has to augment and help in maturation of so many organs. We have noticed the pyramidal lobe in our collection of human fetal tissue. Several workers, Marshall CF [1891], Maria et al [2007], Joshi et al [2010], Lokanadham et al [2012], Enayetullah et al [2013], Lattupali H [2014], in the past have enriched the literature regarding the pyramidal lobe. Present study has been conducted on 52 human fetuses obtained from Department of Obstetrics and Gynaecology, G.M.C. Haldwani (U.K.). Fetuses were dissected and detailed observation of morphology of thyroid gland and pyramidal lobe were recorded. We have also taken biopsy material from pyramidal lobe and thyroid gland, and did histological processing and studied under light microscopy. On histological finding, Pyramidal lobe of fetus [IUL 22 wks] showed small follicles lined with cuboidal epithelium. Interfollicular spaces at some places appear cellular. Parafollicular cells were also present. Section of thyroglossal duct also seen lined by epithelium. Another fetus [IUL26wks] showed functional follicle filled with colloid with rich vascularity. Fetus [IUL 36.5wks] showed loss of follicular arrangement and loss of colloidal material.

Thus it can be concluded that pyramidal lobe became functional along with thyroid lobe and at term functional loss of pyramidal lobe is observed in respect to lobe because of less vascularity.

**KEYWORDS :** Thyroid gland, Pyramidal lobe, Levator glandulae thyroidae.

## INTRODUCTION

The thyroid gland is the first endocrine gland to start developing in the embryo [1]. Its organogenesis begins when the median endoderm cells starts getting thick, forming a diverticulum, in the primitive pharynx floor. This diverticulum descends, and at the seventh week of pregnancy it stops at cervical spine height [2]. It is a highly vascular endocrine gland which is placed anterior in the neck, extending from fifth cervical to the first thoracic vertebrae.

The gland is composed of two lateral lobes which are connected by a narrow median isthmus [3]. The thyroid gland is unique among the human endocrine glands in that it stores large amount of hormone in an inactive form within extracellular compartments called follicles; in contrast, other endocrine glands store only small quantities of hormones in intracellular sites [4]. A conical

pyramidal lobe often ascends towards the hyoid bone from isthmus or adjacent part of either lobe. The levator of the thyroid gland-muscular levator glandulae thyroidae, sometimes descends from the hyoid bone to the isthmus or pyramidal lobe [5,6].

Nearly many people think that the thyroid gland is an organ made up of two lobes. Sometimes radiological reports show left thyroid or right thyroid. Fact is, there are four components of thyroid gland, the right and left lobes, the isthmus that crosses the wind pipe and joins those lobes, and the pyramidal lobe, a superior extension of variable length that comes up from the isthmus. Pyramidal lobe is often present and regarded as normal. It may originate from the isthmus or one of the lobes of thyroid or often from left. It may vary from a short stump to a process reaching the hyoid bone i.e. Levator glandulae thyroidae.

---

## Address for Correspondence :

Dr. Navodita Chaudhary [JR111]

Room no.-25, New Diamond Hostel

Govt Medical College, Haldwani Nainital (U.K.)

Pin code: 263139

Mob: 9453577831

## **MATERIAL AND METHOD**

52 human fetuses (m=28, f=24) of different gestational age, which were collected from Department of Obstetrics and Gynecology, G.M.C.Haldwani (U.K.) All fetuses were preserved in 10% formalin by multiple injection method [7]. Various parameters were recorded eg length, width, thickness of lobes and weight of the thyroid gland. The neck region was dissected to study the morphology and histology of thyroid gland.

## **OBSERVATIONS**

After removal of layers of neck we observed pyramidal lobe arising from lateral lobe or isthmus (Fig1). The pattern of distribution of pyramidal lobe is described as in table I.

According to table I, the incidence of the pyramidal lobe in the present study observed to be 19.23% (10 in 52 fetuses). In maximum number of cases pyramidal lobes were arising from left side of the isthmus. The present study showed the male preponderance (60%).

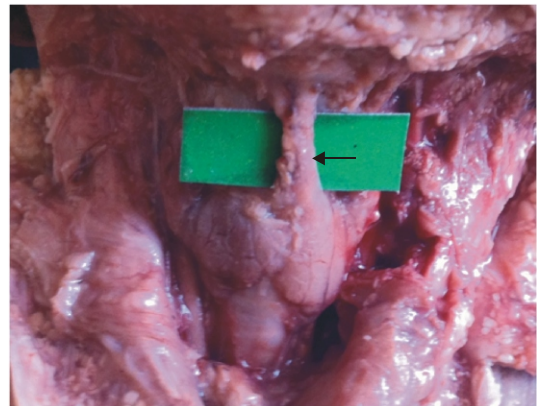
Histology of pyramidal lobes:- At 22 weeks stage of development as in fig2, follicles in pyramidal lobe appear to be smaller in size. Follicles are lined with cuboidal epithelium. Nucleus of the follicular cells appears to be more condensed. Interfollicular space at some places appears to be more cellular without disposition of thyroid homogenous mass. Parafollicular cells are also seen at some places. As shown in fig 3, thyroglossal duct has also been noticed in histology of pyramidal lobe at 22 weeks. It is lined with cuboidal epithelium. Surrounding connective tissue core also seen.

At 26 weeks stage of development pyramidal lobe showed thyroid follicles and thyroid gland like cuboidal epithelium. Nucleus appears to be oval and more enlarged i.e. there is nucleus prominence. Follicular space filled with pinkish homogenous mass suggestive of colloid material indicating the functional status of early stage (fig 4). In surrounding follicle, we notice rich vascularity. Some of the follicular cells appears to be more aggregated at

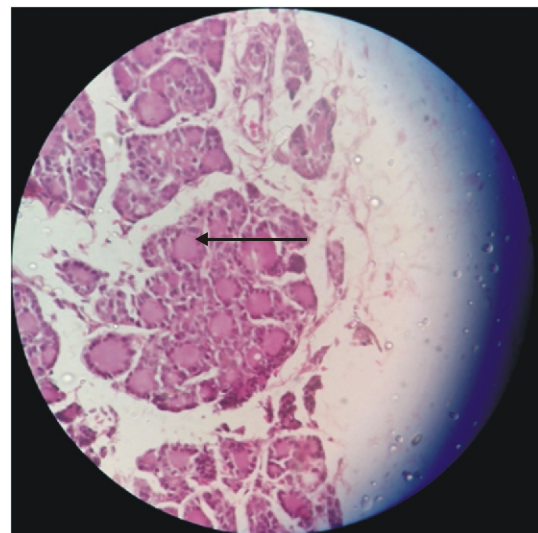
places without showing surrounding follicular space. As shown in fig 5, Connective tissue is also seen in between the follicles. Interfollicular space much more filled with the cellular structure having oval nucleus.

Thus above findings are suggestive of thyroid tissue associated with pyramidal lobe became functional before rest of thyroid.

In present study, out of 52 fetuses levator glandulae thyroideae was found in 10 (19.23%) fetuses of which 7 (70%) male and 3 (30%) were females. Mostly levator glandulae thyroideae had association with apex of the pyramidal lobe to the hyoid bone. In 2 cases only levator glandulae



**Fig 1: Pyramidal lobe arising from left side of isthmus (in situ) (Arrow indicates pyramidal lobe)**



**Fig2: photomicrograph of pyramidal lobe at 22 weeks with H/E stain ×400 [continuous and broken arrows show parafollicular cell]**

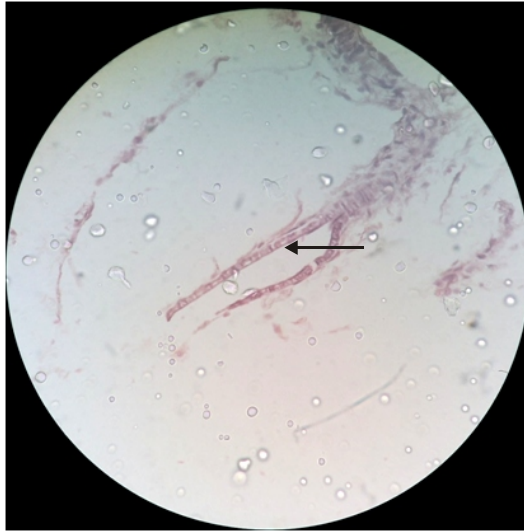


Fig3: photomicrograph of pyramidal lobe at 22 weeks with H/E stain x400 [Arrow shows lining epithelium of thyroglossal duct]

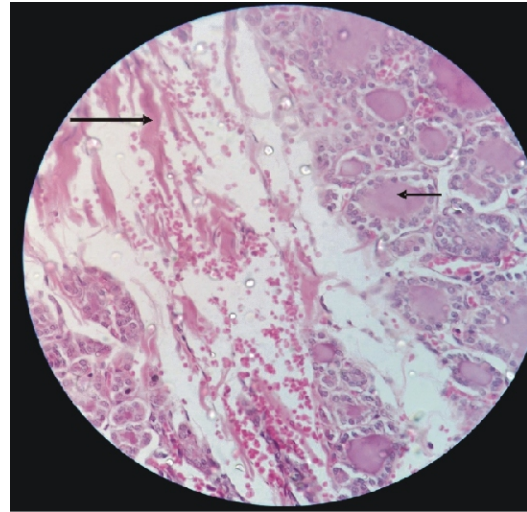


Fig 5: photomicrograph of pyramidal lobe at 26 weeks with H/E stain x400 [small arrow showing follicle filled with colloid, large arrow showing connective tissue ]

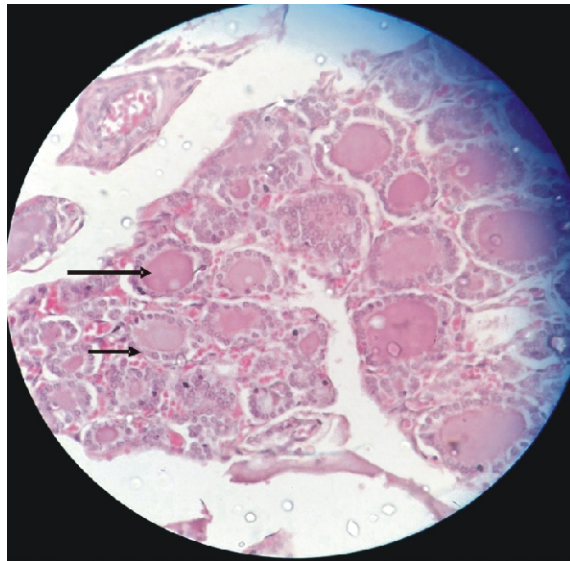


Fig4: photomicrograph of pyramidal lobe at 26 weeks with H/E stain x400

[ large arrow showing colloid material within the follicle, small arrow showing lining epithelium of the follicle]

thyroideae was present without pyramidal lobe. The levator glandulae thyroideae was fibrous in nature.

TABLE I : - Showing the Distribution of Pyramidal lobe in Fetal Thyroid Gland in Present Study

S. no.	Gestational age in weeks	Sex	Weight of fetus in gms	Anomaly	Weight of thyroid gland in mgs
1	15	M	57	On right side of isthmus	137
2	18	M	173	Mid of isthmus	50
3	19.5	F	212	On left side of isthmus	140
4	22	M	435	On left side of isthmus	220
5	22	F	513	From left lobe of thyroid gland	240
6	26	M	1038	On left side of isthmus	484

*Pyramidal Lobe And Levator Glandulae Thyroidae In Human Fetal Thyroid Gland.*

7	31.5	F	1449	On left side of isthmus	475
8	32.5	F	1811	On left side of isthmus	510
9	33.5	M	1608	On right side of isthmus	522
10	36.5	M	2770	On left side of isthmus	640

According to table I, the incidence of the pyramidal lobe in the present study observed to be 19.23% (10 in 52 fetuses). In maximum number of cases pyramidal lobes were arising from left side of the isthmus. The present study showed the male preponderance (60%).

**Table II :- Showing The Incidence of the Pyramidal Lobe as recorded in previous years**

S. no.	Authors	Incidence %	year	Site of origin of pyramidal lobe
1	Marshall C.F. (8)	43	1895	
2	Christopher(19) and Hollinshed (20)	43 to 80	1954	
3	Izenstark et al(21)	35	1969	
4	Hamilton WJ(22)	40	1976	From left side of isthmus
5	Dozois (23)	50	1977	
6	Pansky(24)	50	1982	
7	Enayetullah(12)	50	1996	More on left side
8	De Groot(25)	15	2001	
9	Begum et al(26)	26.7	2004	More on left side

10	Harjeet et al(27)	28.	2004	
11	Braun et al(28)	55	2007	More on left side
12	Sultana et al(29)	50	2008	
13	Ranade et al(30)	58	2008	
14	ASM Nuruinnabi(31)	41.67	2009	
15	Joshi et al(32)	37.77	2010	
16	Tanriover et al(33)	57.8	2011	More on left side of isthmus
17	Lokanadham et al(34)	76.8	2012	
18	Milojevic et al(17)	55.2	2013	
19	Hussain et al(18)	40.6	2015	
20	Present study	19.23	2015	More from left side of isthmus

**DISCUSSION**

Thyroid gland is well known for its developmental anomalies, which include persistence of pyramidal lobe, thyroglossal cyst, agenesis of thyroid gland, agenesis of isthmus alone or of the aberrant thyroid gland etc [8] . Bourgeri (1831) [9] described and illustrated a muscle which he called as "hyo-thyroidien", which occupied the place of the pyramidal lobe. Jackson (1931) [10] performed a histomorphometric study of the sections of the thyroid gland of men and found that the follicles increased in length and breadth with age. He also documented that the thyroid tissue was also present in the pyramidal lobe. Ross [11] in 1995 described the origin of the pyramidal lobe. He defined it as an embryologic remnant of the caudal end of the thyroglossal duct. Enayetullah (1996) [12] found the pyramidal lobe and the levator glandulae thyroideae in 50% and 32% of cases respectively. Geraci et al [13] in 2008 identified the pyramidal lobe in 50% of the cases. Devi sankar et al [14] (2009), described about

congenital anomalies of thyroid gland. According to them, Persistence of pyramidal lobe and thyroglossal duct cyst are the commonest anomalies of thyroid gland while the rare anomalies are agenesis of thyroid gland either partial or total, aberrant thyroid glands and agenesis of isthmus. Zivic et al [15] in 2011 during their study stated that the pyramidal lobe was found in 61% of adults.

The lobe of Lalouette (pyramidal) was found more often in women (61.96%) than in men (50%) and more often (67.3%) in persons less than 50 years old than in those older than 50 (54.2%). Phukon et al [16] in 2012 during routine cadaveric dissection observed a pyramidal lobe arising from the medial border of the right lobe of the thyroid gland. Milojevic in 2013 [17] studied 58 adult human thyroid glands and stated that the Pyramidal lobe was found in 55.2% of cases. Hussain et al [18] in 2015 during their study in 32 cadavers found that the Pyramidal lobe was found in 40.6% of cases. Various authors have reported different incidences of pyramidal lobe as given below in table II.

From above discussion as in table II, it is clear that in literature the incidence of pyramidal lobe varies between as low as 15 to as high as 76.8%. While during our study we found the incidence of the pyramidal lobe to be 19.23% which lies between above values.

According to Standring [35], musculus levator glandulae thyroideae is a fibrous or fibromuscular band that stretches from the pyramidal lobe or upper border of isthmus of thyroid gland to the body of the hyoid bone, usually on the left side. According to Hamilton and Mossman [36], it may be considered as a fibrous or a muscular replacement of the pyramidal lobe. Godart reported a case in which the structure was indeed muscular, on the basis of the nitric acid test for the muscle. Soemmerring's muscle is the same as the hyo-thyro-glandulaire of Poite, the levator glandulae thyroideae superficialis medius et longus of Krause and the musculus thyroideus of Merkel; its usual full name being 'levator glandulae thyroideae of Soemmerring'.

## **CONCLUSION**

Available literature revealed the incidence of the pyramidal lobe varying from 15% to 76.8%. Pyramidal lobe in majority of cases arising from left

side of the isthmus and male preponderance was also observed. In the present study, we have observed 19.23% incidence of pyramidal lobe and it was more observed in male. Our observations are comparable with the observations of some authors. Histology of pyramidal lobe has not been given due attention and perhaps the citation appears to be very limited. Since the pyramidal lobe is a normal component of the thyroid gland, of varying position and size, with pathological changes in benign and malignant diseases, it should always be examined during thyroid surgery and mandatorily removed in total and subtotal thyroidectomies.

In present study we observed histological finding at different gestational age

-At 22 weeks of intrauterine life, pyramidal lobe showed follicular organization similar to the lateral lobe. Less colloidal material seen in the follicular lumen.

-At 26 week of intrauterine life, follicle were filled with colloidal material suggestive of the achieving the functional status of this pyramidal lobe.

## **REFERENCES**

1. Sadler TW. Head and Neck In: Langman's medical embryology, 7th Ed, Williams & Wilkins, Baltimore, USA, 1995, p. 329-330.
2. Perone D, Teixeira SS, Clara AS, Santos, DC and Nogueira CR. Aspectos genéticos do hipotireoidismo congênito. Arquivos Brasileiros de Endocrinologia & Metabolismo, 2004, vol. 48 (n.1), p. 62-69.
3. Standring S, Herold E, Healy JC, Johnson D, Williams A. In: Endocrine system. Gray's Anatomy. 38th ed. Elsevier, Churchill Livingstone; 2005; 1891-92.
4. Burkitt H.G., Young B. and Heath J.W. In Wheater's Functional Histology, A Text and Colour Atlas, 3rd ed., Churchill Livingstone London., 1993, p.309.
5. Williams PL, Bannister LK, Berry MM, Collins P, Dyson M, Dussek JE, Ferguson MWJ. Grays Anatomy. 38th Ed, Churchill Livingstone, Edinburgh, 2000, p.1891-1892.

6. Berkovitz BK. editor. Neck and upper aerodigestive tract. In: Standring S, Ellis H, Heally JC, Johnson D, Williams A, Collins P, Wigeley C. editors. *Gray's Anatomy: The anatomical basis of clinical practice*. 39th ed. Edinburgh: Elsevier Churchill Livingstone; 2005. p. 560-4.
7. Ajmani. Textbook of 'Embalming principles and Legal Aspects', 1996, pp: 131-135.
8. Marshall CF. Variation in the form of the thyroid in man. *J Anat physiol*. 1895, 29;234-39.
9. Bourgerie JM. *Traite complet d'anatomie de l'homme, comprenant la medecine operatoire, avec planches lithographiees d'apres nature par NH Jacob. Atlas. Paris. C. [-A.] Delaunay 1831; Tome II: 90, 1836; Tome IV: 91. French. Cited by Ranade AV, Rai R, Pai MM, Nayak SR, Prakash, Krishnamurthy A, Narayana S. Anatomical variation of the thyroid gland: possible surgical implications. Singapore Med J, 2008,49;831-34.*
10. Jackson JL. The shape and size of human thyroid follicle in health and disease. *Anatomical record*. 1931,48; 220-37.
11. Ross MH, Romrell LJ, Kaye GI. *Histology: a text and atlas with correlated cell and molecular biology*. 3rd ed. Baltimore: Lippincott Williams & Wilkins; 1995. p. 603-606.
12. Enayetullah M. Gross and histomorphological study of the thyroid and parathyroid glands in Bangladeshi people (M.Phil.Thesis). Dhaka:University of Dhaka;1996.
13. Geraci G, Pisello F, Li Volsi F, Modica G, Sciumè C. The importance of pyramidal lobe in thyroid surgery. *G. Chir*. 2008, 29(11-12); 479-82.
14. Devi Sankar K, Sharmila Bhanu P, Susan PJ, Gajendra K. Agenesis of isthmus of thyroid gland with bilateral levator glandulae thyroideae. *Int J Anat Vari*, 2009, 2; 29-30.
15. Zivic R, Radovanovic D, Vekic B , Markovic I, Dzodic R, Zivaljevic V. *Surgical Anatomy Of The Pyramidal Lobe And Its Significance In Thyroid Surgery: Sajs VoL 49, No. 3, August 2011.*
16. Phukon M J, Dutta R, Reddy GN, Bhargabhi, Syed NA. Right Sided Pyramidal Lobe of Thyroid Gland- A Case Report. *Int J Biol Med Res*. 2012, 3(2); 1839 – 1841.
17. Milojevic B, Tosevski J, Milisavljevic M, Babic D, Malikovic A. Pyramidal lobe of the human thyroid gland: an anatomical study with clinical implications. *Rom J Morphol Embryol* 2013, 54(2); 285–289.
18. Kafeel Hussain A, Sujatha N, Hemanth Kommuru, Bhavani Prasad, SwayamJothi. *Morphological Variations of the Thyroid Gland. IOSR Journal of Dental and Medical Sciences (IOSR-JDMS). Volume 14, Issue 3 Ver. I (Mar. 2015); PP 18-24.*
19. Christopher, F. *A Textbook of Surgery*, 4th ed W.B. Sarendens Co ,Philadelphia,1954, 274.
20. Hollinshead W.H. *Anatomy for Surgeons : Vol 1 Paul B Hoeber, Inc., Newyork, Philadelphia. 1954, 274.*
21. Izenstark JL, Horwitz NH. The pyramidal lobe in thyroid imaging. *Journal of Nuclear Medicine*. 1969,10; 519-24.
22. Hamilton WJ. *Textbook of human anatomy*, 2nd edition, The Macmillan Press Ltd, London. 1976,488-493.
23. Dozois RR, Beahrs OH. *Surgical anatomy and technique of thyroid and parathyroid surgery. Surgical Clinics of North America. 1977, 57; 647-660.*
24. Pansky B. *Review of medical embryology. Macmillan Publishing Co., New York, 1982, 136-37.*
25. DeGroot LJ, Jameson JL. editor. *Endocrinology*, 4th edition, WB Saunders company, Philadelphia. 2001, 1268-77.
26. Begum M. Gross and histomorphological Study of human postmortem thyroid gland in Bangladeshi People (M.Phil. Thesis). Dhaka: University of Dhaka. 2004, 1-120.
27. Harjeet A, Sahni D, Jit I, Aggarwal AK. The shape,the measurement and the weight of the thyroid gland in northwest Indians. *Surg Radiol Anat* 2004,26;91-95.

28. Braun EM, Windish G, Wolf G, Hausleitner L, Anderhuber F. The Pyramidal lobe: clinical anatomy and its importance in thyroid surgery. *Surg Radiol Anat.* 2007 Feb, 29(99991);21-7.
29. Sultana SZ, Mannan S, Ahmed MS, Rahman MM, Khan MK, Khalil M. An anatomical study on pyramidal lobe of thyroid gland in Bangladeshi People. *Mymensingh Med J.* 2008, 17(1); 8-13.
30. Ranade A V, Rai R, Pai M M, Nayak S R, Prakash, Krisnamurthy A, Narayana S. Anatomical variations of the thyroid gland: possible surgical implications. *Singapore Med J.* 2008, 49 (10) ; 831-34.
31. Nuruinnabi ASM, Alim A, Mehbub S, Kishwara S, Begum M, Khatun M, Ara S. Morphological and Histological study of the Pyramidal lobe of the thyroid gland in Bangladeshi People. A postmortem study. *Bangladesh J. of Anatomy.* 2009, 7; 94-100.
32. Joshi SD, Joshi SS, Daimi SR and Athavale SA. The thyroid gland and its variations: a cadaveric study. *Folia Morphol (Warsz).* 2010, 69(1) ; 47-50.
33. Tanriover O, Comunoglu N, Eren B, Comunoglu C, Turkmen N, Bilgen S, Kaspar EC, Gundogmus UN, Morphometric features of the thyroid gland: a cadaveric study of Turkish people, *Folia Morphol (Warsz).* 2011, 70(2); 103–108.
34. Lokanadham S, Satheesh Naik K, Subhadra Devi V. Thyroid gland isthmus agenesis in autopsied fetus: Case study *Prime Research on Medicine (PROM).* 2012;2(1); 69-71.
35. Standring S. In: *Gray's Anatomy*, 39th Edition, London: Elsevier Churchill Livingstone. 2006; 561.
36. Hamilton WJ, Mossman HW. editors. *Hamilton, Boyd and Mossman's human embryology: prenatal development of form and function.* 4th ed. London: Williams and Wilkins; 1978;223-6.